

Su M. Lwin, MRCP, MBBS, BSc (Hons)
 Chao-Kai Hsu, MD
 James R. McMillan, PhD
 Jemima E. Mellerio, MD, FRCP, MBBS, BSc (Hons)
 John A. McGrath, MD, FRCP, FMedSci

Author Affiliations: St John's Institute of Dermatology, King's College London, Guy's Campus, London, England (Lwin, Hsu, Mellerio, McGrath); Viapath, St Thomas' Hospital, London, England (McMillan).

Corresponding Author: John A. McGrath, MD, FRCP, FMedSci, Dermatology Research Laboratories, Floor 9 Tower Wing, Guy's Hospital, Great Maze Pond, London SE1 9RT, England (john.mcgrath@kcl.ac.uk).

Published Online: May 25, 2016. doi:[10.1001/jamadermatol.2016.1187](https://doi.org/10.1001/jamadermatol.2016.1187).

Conflict of Interest Disclosures: None reported.

Funding/Support: This study was supported in part by the Department of Health via the UK National Institute for Health Research (NIHR) Comprehensive Biomedical Research Centre award to Guy's and St Thomas' National Health Service (NHS) Foundation Trust in partnership with King's College London and King's College Hospital NHS Foundation Trust.

Role of the Funder/Sponsor: The funding institutions had no role in the design and conduct of the study; collection, management, analysis, and interpretation of the data; preparation, review, or approval of the manuscript; and decision to submit the manuscript for publication.

Additional Contributions: We thank the patient for granting permission to publish this information. We also thank Lu Liu, PhD, Viapath, St Thomas' Hospital, London, England, and Rashida Pramanik, BSc (Hons), St John's Institute of Dermatology, King's College London (Guy's Campus), London, England, for technical support; and Debra E. Lomas, MA MB BChir, MRCP, Department of Dermatology, Great Ormond Street Hospital for Children NHS Foundation Trust, London, England, for administrative and material support. None received any compensation for their contributions.

1. Tsuge I, Morishita M, Kato T, et al. Identification of novel FATP4 mutations in a Japanese patient with ichthyosis prematurity syndrome. *Hum Genome Var*. 2015;2:15003. doi:[10.1038/hgv.2015.3](https://doi.org/10.1038/hgv.2015.3).
2. George R, Santhanam S, Samuel R, et al. Ichthyosis prematurity syndrome caused by a novel missense mutation in FATP4 gene—a case report from India. *Clin Case Rep*. 2015;4(1):87-89.
3. Klar J, Schweiger M, Zimmerman R, et al. Mutations in the fatty acid transport protein 4 gene cause the ichthyosis prematurity syndrome. *Am J Hum Genet*. 2009;85(2):248-253.
4. Sobol M, Dahl N, Klar J. FATP4 missense and nonsense mutations cause similar features in ichthyosis prematurity syndrome. *BMC Res Notes*. 2011;4:90.
5. Kiely C, Devaney D, Fischer J, Lenane P, Irvine AD. Ichthyosis prematurity syndrome: a case report and review of known mutations. *Pediatr Dermatol*. 2014;31(4):517-518.
6. Khnykin D, Rønnevig J, Johnsson M, et al. Ichthyosis prematurity syndrome: clinical evaluation of 17 families with a rare disorder of lipid metabolism. *J Am Acad Dermatol*. 2012;66(4):606-616.

Life-Threatening Cutaneous Bleeding in Childhood Klippel-Trenaunay Syndrome Treated With Oral Sirolimus

Klippel-Trenaunay syndrome (KTS) is characterized by the triad of cutaneous capillary malformations (port-wine stains), asymmetrical disturbed growth of soft tissues and/or bone, and venous and lymphatic malformations.¹ Prolonged and recurrent cutaneous bleeding from ulceration of the capillary and/or venous and/or lymphatic malformation can be life-threatening.² We report for the first time to our knowledge a case of Klippel-Trenaunay syndrome treated by oral sirolimus.

Report of a Case | A 13-month-old boy from Conakry, Guinea, was referred for assessment of recurrent cutaneous bleeding of the right lateral thigh complicated by chronic anemia. The par-

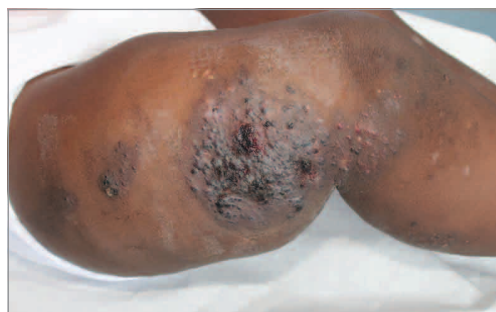ents had noted bleeding, either spontaneous or during dressing change, for 2 months despite the application of hemostatic dressings. Physical examination revealed a hypertrophic lower right limb with multiple port-wine stains centered by tumefactions 2 to 13 cm long composed of grouped hemorrhagic vesicles and crust (Figure 1A). Laboratory investigations revealed the following: hemoglobin level, 8.8 g/dL (normal range [NR], 10-14 g/dL), hematocrit, 29% (NR, 30%-42%), platelet count of $403 \times 10^3/\mu\text{L}$ (NR, $150 \times 10^3/\mu\text{L}$ to $400 \times 10^3/\mu\text{L}$), fibrinogen, 30 mg/dL (NR, 150-400 mg/dL), and D-dimer, greater than 4 $\mu\text{g/mL}$ (NR, <0.5 $\mu\text{g/mL}$). (To convert fibrinogen to micromoles per liter, multiply by 0.0294; D-dimer to nanomoles per liter, multiply by 5.476.) Magnetic resonance imaging (MRI) of the right leg showed a microcystic lymphatic malformation with muscular infiltration of the posterior compartment of the thigh and hypoplasia of the deep veins associated with a persistent embryonic lateral marginal vein of the thigh (Figure 2A). A diagnosis was made of KTS complicated by chronic cutaneous bleeding induced by extensive microcystic lymphatic cutaneous malformation and lateral thigh vein. Due to the partially atretic deep venous system and the extensive muscular infiltration of the lymphatic malformation, treatment by surgery, sclerotherapy, catheter embolization, and compression were ruled out. Photocoagulation using the Nd:YAG or fractional carbon dioxide laser was infeasible due to the need for multiple sessions under general anesthesia and the risk of recurrence.

After informed parental consent, treatment with oral sirolimus was started at 0.8 mg/m² per dose twice daily along with cotrimoxazole for *Pneumocystis* prophylaxis. The bleeding stopped completely after 48 hours. Subsequent dosing of sirolimus was adjusted to 1 mg/m² per dose to maintain a goal drug level around 10 ng/mL. The patient's anemia was corrected and D-dimer level normalized 1 and 5 months, respectively, after starting sirolimus treatment. In the following 6 months, a consistent and gradual reduction in the thickness of the tumefaction and its hemorrhagic component (Figure 1B) was noted and confirmed by MRI (Figure 2B). An attempt to terminate sirolimus treatment resulted in a rapid relapse of minimal cutaneous bleeding after 2 to 3 days, and sirolimus therapy was restarted promptly at the same dosage. No clinically significant adverse effect was observed after 10 months, and treatment by oral sirolimus was maintained at the same dose.

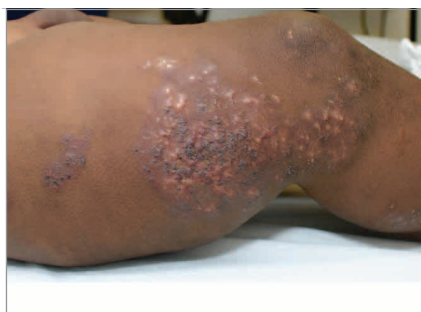Discussion | Recent observations have shown that KTS is caused by heterozygous somatic gain-of-function *PIK3CA* mutations in a mosaic pattern, leading to inappropriate activation of the P13K/AKT/mTOR pathway, and belongs to the *PIK3CA*-related overgrowth spectrum (PROS).³ Recent publications emphasize the potential interest of sirolimus, an inhibitor of mTOR activity, as a treatment option for cutaneous vascular malformations and PROS.^{4,5} Sirolimus has been used successfully with a good safety profile in more than 70 case reports of vascular anomalies with lymphatic components,⁶ and phase 2 studies are ongoing to assess its efficacy and safety in various complex vascular malformations, including KTS (clinicaltrials.gov [NCT00975819](https://clinicaltrials.gov/ct2/show/study?term=NCT00975819), [NCT02509468](https://clinicaltrials.gov/ct2/show/study?term=NCT02509468), and [NCT01811667](https://clinicaltrials.gov/ct2/show/study?term=NCT01811667)).

Figure 1. Clinical Efficacy of Sirolimus in Treating Lymphatic Malformation of Klippel-Trenaunay Syndrome

A Before treatment



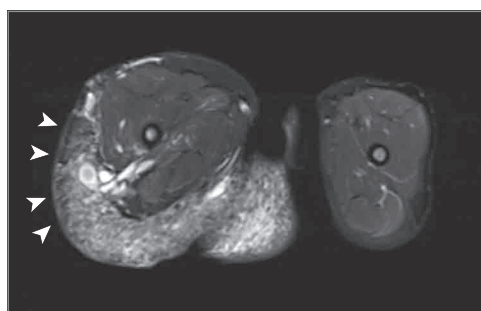
B After 6 months of oral sirolimus treatment



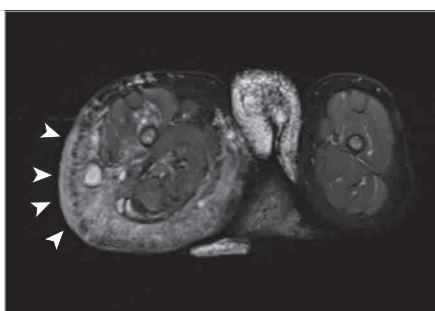
A, Hypertrophy of the lower right limb, multiple port-wine stains on the outside surface of the thigh and knee centered by lymphatic malformations 2 to 13 cm long and composed of grouped hemorrhagic lesions, more rarely whitish or translucent, vesicles, and hemorrhagic crusts. B, Significant reduction in the thickness of the lymphatic malformation as well as its hemorrhagic component after 6 months of oral sirolimus treatment.

Figure 2. Magnetic Resonance Imaging Study (T2-Weighted Fat-Saturation Axial Images) of Lymphatic Malformation of Klippel-Trenaunay Syndrome

A Before treatment



B After 6 months of oral sirolimus treatment



A, Microcystic lymphangiomatous cutaneous (arrows) and muscular infiltration of the right thigh. B, Marked reduction of the cutaneous lymphatic infiltration (arrows) after 6 months of oral sirolimus therapy.

For our patient, sirolimus provided rapid and effective control of the cutaneous bleeding complicating a combined venous and lymphatic cutaneous malformation. The drug's efficacy in treating the cutaneous lymphatic malformation appears obvious from the striking regression in the turgidity and hemorrhagic component of the lymphatic vesicles. However, a potentially antiangiogenic action on the lateral thigh vein cannot be excluded. This case report suggests that sirolimus may be an alternative medical treatment for bleeding induced by venous and lymphatic malformation associated with KTS.

Didier Bessis, MD
Hélène Vernhet, MD, PhD
Michèle Bigorre, MD
Isabelle Quéré, MD, PhD
Jochen Rössler, MD

Author Affiliations: Department of Dermatology, Saint-Eloi Hospital, University Hospital of Montpellier, Montpellier, France (Bessis); University of Montpellier, Montpellier, France (Bessis); INSERM U1058, Montpellier, France (Bessis); Department of Radiology, Lapeyronie Hospital, University Hospital of Montpellier, Montpellier, France (Vernhet); Department of Pediatric Infantile Surgery, Lapeyronie Hospital, University Hospital of Montpellier, Montpellier, France (Bigorre); Department of Internal Medicine, Saint-Eloi Hospital, University Hospital of Montpellier, Montpellier, France (Quéré); Department of Pediatric Oncology and Hematology, Arnaud de Villeneuve Hospital, University Hospital of Montpellier, Montpellier, France (Rössler).

Corresponding Author: Didier Bessis, MD, Department of Dermatology, Saint-Eloi Hospital, University Hospital of Montpellier, 80 avenue A Fliche, 34295 Montpellier CEDEX 5, France (d-bessis@chu-montpellier.fr).

Published Online: May 11, 2016. doi:[10.1001/jamadermatol.2016.1008](https://doi.org/10.1001/jamadermatol.2016.1008).

Conflict of Interest Disclosures: Dr Rössler received research funds from Novartis, Pfizer, and Pierre Fabre. He is a principal investigator in clinical studies sponsored by Bayer, BMS, Helsinn, Infectopharm, Sanofi, Pierre Fabre, and Merck. No other disclosures are reported.

Additional Contributions: We thank the patient's parents for granting permission to publish this information.

1. Oduber CE, van der Horst CM, Hennekam RC. Klippel-Trenaunay syndrome: diagnostic criteria and hypothesis on etiology. *Ann Plast Surg*. 2008;60(2):217-223.
2. Redondo P, Aguado L, Martínez-Cuesta A. Diagnosis and management of extensive vascular malformations of the lower limb, part II: systemic repercussions, diagnosis, and treatment. *J Am Acad Dermatol*. 2011;65(5):909-923.
3. Luks VL, Kamitaki N, Vivero MP, et al. Lymphatic and other vascular malformative/overgrowth disorders are caused by somatic mutations in PIK3CA. *J Pediatr*. 2015;166(4):1048-54.e1, 5.
4. Shirazi F, Cohen C, Fried L, Arbiser JL. Mammalian target of rapamycin (mTOR) is activated in cutaneous vascular malformations in vivo. *Lymphat Res Biol*. 2007;5(4):233-236.
5. Vahidnezhad H, Youssef An L, Uitto J. Molecular genetics of the PI3K-AKT-mTOR pathway in genodermatoses: diagnostic implications and treatment opportunities. *J Invest Dermatol*. 2016;136(1):15-23.
6. Nadal M, Giraudeau B, Tavernier E, Jonville-Bera AP, Lorette G, Maruani A. Efficacy and safety of mammalian target of rapamycin inhibitors in vascular anomalies: a systematic review. *Acta Derm Venereol*. 2015. Epub ahead of print.